



## Clinical Performance of Full Arch Implant Monolithic Zirconia Rehabilitations - A Retrospective Study

Miguel Nunes Vasques<sup>1</sup>, Marco Infante da Câmara<sup>2</sup>, Fernando Duarte<sup>3\*</sup> and José Manuel Mendes<sup>2</sup>

<sup>1</sup>Clinical Assistant in Oral Surgery and Oral Medicine Department at Instituto Universitário de Ciências da Saúde, Portugal

<sup>2</sup>Professor at Instituto Universitário de Ciências da Saúde, Portugal

<sup>3</sup>CEO and Clinical Director of Clitrofa - Trofa, Portugal

\*Corresponding Author: Fernando Duarte, CEO and Clinical Director of Clitrofa - Trofa, Portugal.

Received: July 05, 2021; Published: August 30, 2021

### Abstract

**Introduction:** Population aging and total edentulism are two interrelated factors. The United Nations department of public information states that the world population by 2015 was 7.3 billion people and the World Health Organization states that 26% of adults over the age of 74 will have lost all their permanent teeth, we are facing a public health problem that can be solved by using dental implants. Total fixed rehabilitations on implants are very well documented in the scientific literature. Various types of prosthetic materials may be used such as metalloacrylic, metallocomposite and metaloceramic. The most frequent complications of this type of oral rehabilitation are the fracture of the acrylic teeth, wear of the natural antagonist teeth, ceramic chippings, lack of passivity and repairs of fractured metal structures.

The use of zirconia for the execution of superstructures is a more recent modality of treatment. Rehabilitation in zirconia has been increasing in popularity due to its excellent mechanical and biological properties. Zirconia structures with cutback and subsequent application of ceramics often have frequent chippings. In order to find a solution, monolithic multilayer zirconia blocks have been developed to perform one piece fixed implant restorations. With this improvement it is expected reduction of fractures obtaining more esthetic fixed prostheses with high resistance and minimum occlusal adjustments.

**Purposes:** This retrospective study has as main objective to evaluate the clinical performance of the full arch rehabilitation on implants using monolithic zirconia Noritake Katana Kuraray ML®. The secondary objectives are the evaluation of the average weight of each structure in zirconia, influence of the distal cantilever as a risk factor in the fracture of the structure in each dental arch, incisal edge chippings, fracture of cusps or zirconia structure, evaluation of the level of wear of the antagonistic arches and dicementation of the titanium interfaces of the zirconia structure.

**Materials and Methods:** Clinical data collection of the full arch implant restorations carried out in the scope of the 5th, 6th and 7th Editions of Postgraduate Course in Oral Implantology at Cespu Clinic - Famalicão Unit - Portugal.

Clinical data were extracted meeting the data protection requirements of patients routinely treated in this course. The present study was performed in 21 patients in a total of 29 dental arches, C1 MIS® and Straumann BLT® implants were placed and restored with monolithic Zirconia Noritake Katana Kuraray® ML using Wieland® milling machine. In 1 arch were placed 4 straight implants, 19 arches were placed 4 implants by the All-on-4 technique, however 9 arches received 6 implants. Patients age ranged from 32 to 77 years and the follow-up time was from 6 to 38 months. The data collection form was completed and informed consent was signed by all patients involved in this study. All edentulous patients were treated following the same clinical protocol and all rehabilitations were performed by the same dental technician. Radiographic records include initial panoramic x-ray and computerized axial tomography, postoperative and final panoramic x-ray plus periapical x-ray were also taken using RVG Owandy®. During the annual follow-up panoramic x-ray and periapical x-ray were taken. Finally, the performance of the fixed full arch screw-retained monolithic zirconia rehabilitation was evaluated in all patients.

**Results:** In this study, 76% of the patients treated with monolithic zirconia did not have any type of complications, 6,9% presented antagonistic wear, 10,3% presented minor multi-unit abutment loosening, 3,4% presented minor prosthetic screw loosening and 3,4% had a fracture of the structure.

**Conclusion:** The monolithic zirconia Noritake Katana® multilayer ML milled in Wieland® Cad-Cam to perform the fixed rehabilitation of total edentulous arches is a valid treatment option. Featuring a success rate of 96,6%. The result in this study show a high success rate in terms of function, aesthetics and phonetics achieving high patient satisfaction.

**Keywords:** *Monolithic Zirconia; Zirconia Supra-Structure; Tetragonal Polycrystalline Zirconia Stabilized  $\gamma$ -ztp; Fracture; Zirconia Prostheses*

## Introduction

Total edentulism is a crippling condition in the quality of life of the world population and with the aging of the population it increasingly affects a larger number of people. According to the World Health Organization (WHO) 69% of adults between 35 and 44 years old have lost at least one tooth and 26% of adults over the age of 74 years old will have lost all their permanent teeth. In 1997, the number of edentulous people was less than 33 million; in 2000 it was 35 million, in 2010 it was about 36 million and in 2020 it will be almost 38 million, which means that we are facing a global health problem [1,2].

Per-Ingvar Branemark in 1983, at Gotemborg University introduced to the scientific world the concept of Osseointegration and revolutionized the way in which a total edentulous person may be rehabilitated. Total fixed rehabilitations over implants are very well documented in the scientific literature and provide the patient with good masticatory efficacy [4-9]. In fixed implant-supported rehabilitations, several types of materials may be used, namely metalloacrylic, metallocomposite and metalloceramic [3,4,10].

The most frequent complications of this type of rehabilitation are in metalloacrylic the fracture of acrylic teeth and in metalloceramic the wear of antagonist natural teeth, ceramic chipping, sometimes lack of passivity of metal structures, especially when performed with techniques of foundry and fractures of metallic infrastructure [4]. The use of zirconia for the execution of superstructures is a widely used treatment modality [4,8,10]. Zirconia rehabilitation has been increasing in popularity due to its excellent mechanical properties and biocompatibility with gingival tissues [5,10,11]. Zirconia structures with cutback and subsequent ce-

ramic application show frequent chipping [4-15]. The use of Monolithic Zirconia Cad-Cam blocks in total fixed rehabilitations reduces the possibility of fracture and chipping, obtaining fixed prostheses with high strength and minimal occlusal adjustments [6,7,9,16-18].

Position and angulation of the posterior implants are also very important, Krekmanov L., *et al.* presented a study with great relevance where they demonstrated that the success rate of tilted implants in the upper jaw (98%) and in the lower jaw (100%) with a gain in posterior support of fixed prostheses of 6.5 mm in the mandible and 9.3 mm in the maxilla [19]. Malo P., *et al.* in 2011 reported some multi-units or mini-abutments loosening but with high success rates with the use of tilted implants [22].

English C in 1990, proposed that the distal cantilever of fixed prostheses should never exceed 1.5 times the AP spread, stressing that in the mandible we can safely reach 12 mm cantilevers and that in the maxilla, due to the poorer bone density, the cantilever should not exceed 8 mm [31].

Regarding the prosthetic materials, Linkevicius T in 2015 and 2017 cites that the peri-implant tissue response is significantly better with zirconia [32,33].

Bidra A in 2017, in a systematic review of 12 articles, totaling 285 dental arches, reported 1.4% failure rate due to fracture of the zirconia structure and reported 14.7% of stratified zirconia fracture (42 cases) and advised zirconia monolithic only with stratification of the gingival part to correct these fracture problems [34].

Adar P in 2017, mentions that most zirconia only have a single color that forces to inject color to make the restorations more natu-

ral and also mentions that monolithic zirconia is more economical compared to layered zirconia, which is more resistant and that there will be no appearance of chipping because it is performed in one piece [36].

Finally, Caramês J in 2015, carried out a study in 14 totally edentulous patients with maxillary and mandibular monolithic zirconia rehabilitations with a follow-up of 3 to 24 months using Prettau zirconia and digital cutback of the buccal face and subsequent ceramic application. Of the 26 rehabilitated arches, 24 were screwed and 2 were a combination of screwed and cemented. He only reported one chipping on a central incisor in an arch showing a restoration success rate of 96% [41].

### Purpose of the Study

This study aims to evaluate the clinical performance of total fixed implant-supported rehabilitations made of monolithic zirconia, through the analysis of data collected in the 5<sup>th</sup>, 6<sup>th</sup> and 7<sup>th</sup> Editions of the Postgraduate Course in Oral Implantology at Cespu Clinic - Famalicão Unit - Portugal.

As secondary objectives, we highlight the evaluation of the following parameters: a) Quantify gender in this study; b) Characterization of the facial type of the studied patients; c) Presence of bruxism at the end of treatment; d) Identify in how many arches fixed zirconia prostheses were placed; e) Identify the brand, model, diameter and platform of the implants used; f) Identify the surgical technique applied to each of the treated jaws; g) Carrying out temporary immediate loading; h) Characterization of antagonist arches; i) Measurement of patients' OVD; j) Follow-up time for zirconia rehabilitations; k) Average A-P distance; l) Cantilever of each treated arch and middle cantilever; m) Relate the A-P distance and the cantilever of the same prosthesis; n) Evaluate the presence of fractures and/or chippings and their location; o) Assess the presence of wear on the antagonist prosthesis and its location; p) Identify the average weight in grams of upper and lower zirconia prostheses; q) Identify if there is decementation of interfaces, position and its relationship with the facial type; r) Identify whether there is unscrewing the prosthetic abutment (multi-unit/ mini) or the prosthetic screw, its position and its relationship with the facial type; s) Date of last peri-implant maintenance; t) Percentage of smoking patients; u) Evaluate the presence of plaque in zirconia prostheses and its relationship with smoking.

### Materials and Methods

The sample consists of 21 clinical files of patients in a total of 29 dental arches whose ages were between 32 and 77 years old. Follow-up ranged from 6 to 38 months. The sample contains totally edentulous patients rehabilitated with MIS C1® and Straumann BLT® dental implants and fixed rehabilitations milled in monolithic zirconia Noritake Kuraray ML® and Zenotec Wieland® milling machine.

### Inclusion criteria

- All clinical files of totally edentulous patients treated with fixed total rehabilitation in monolithic zirconia from March 2016 to December 2019;
- Processes with complete radiographic record;
- Attendance at the consultation to carry out the questionnaire and clinical evaluation.

### Exclusion criteria

- Cases that did not present complete radiographic information were excluded;
- Patients who missed the clinical evaluation appointment.

### Statistical methodology

- Statistical analysis of data was performed using IBM® SPSS® (Statistical Package for Social Sciences) Statistics version 25.0.0.2.
- Given the nature of the variables involved, we chose to use statistical tools based on the most appropriate analysis for the measurement scales used.

### Results

The total sample consists of 21 processes, of which 8 are related to male elements (38.1%) and the remaining 13 are related to female elements (61.9%).

Table 1 shows the sample characterization data regarding the characteristics of the individuals assessed, as well as the respective limits of the 95% confidence intervals (CI).

Table 2 shows the sample characterization data in terms of prosthesis location.

		N	%	IL for IC of 95%	SL for IC of 95%
Smoker	No	16	76,2%	55,4%	90,3%
	Yes	5	23,8%	9,7%	44,6%
Facial Type	Dolichofacial	1	4,8%	0,5%	20,2%
	Brachyfacial	11	52,4%	31,9%	72,3%
	Mesofacial	9	42,9%	23,7%	63,8%
Eccentric	No	21	100,0%	-	-
	Yes	0	0,0%	-	-
Centric Bru-xism	No	21	100,0%	-	-
	Yes	0	0,0%	-	-

**Table 1:** Summary statistics for patient characteristics.

		N	%	IL for IC of 95%	SL for IC of 95%
Location	Maxilla	15	51,7%	34,1%	69,0%
	Mandible	14	48,3%	31,0%	65,9%
	Total	29	100,0%	.	.

**Table 2:** Location of the prosthesis.

Table 3 presents the sample characterization data in terms of the qualitative variables evaluated for rehabilitation. It is verified that all the rehabilitations were carried out in zirconia, none showed chipping, nor decemented interfaces, nor was a occlusal splint used.

Table 4 summarizes statistics for quantitative measures of rehabilitation.

Table 5 presents the association test results for the presence of plaque and smoking habits.

Figure 1 shows the implant diameter distribution and table 6 presents the diameter distribution according to location.

Table 7 summarizes the diameter distribution according to tooth.

		N	%	IL for IC of 95%	SL for IC of 95%
Surgical technique	4 axials	1	3,4%	0,4%	3,4%
	All on 4	19	65,5%	47,4%	8,8%
	5 axials	0	0,0%	-	-
	All on 6	9	31,0%	16,6%	8,6%
	+6	0	0,0%	-	-
Type of prosthesis	Zirconia	29	100,0%	-	-
Immediate function	No	17	58,6%	40,6%	9,1%
	Yes	12	41,4%	25,0%	9,1%
Antagonist Arcade	Natural	6	20,7%	9,1%	7,5%
	MC	1	3,4%	0,4%	3,4%
	Acrylic	6	20,7%	9,1%	7,5%
	Zr	16	55,2%	37,3%	9,2%
Implant Type	C1 MIS	20	69,0%	51,0%	8,6%
	BLT STRAU-MANN	9	31,0%	16,6%	8,6%
Chipping	No	29	100,0%	-	-
	Yes	0	0,0%	-	-
Fractures	No	28	96,6%	85,0%	3,4%
	Yes	1	3,4%	0,4%	3,4%
Antagonist wear	No	27	93,1%	79,7%	4,7%
	Yes	2	6,9%	1,5%	4,7%
Occlusal Splint	No	29	100,0%	-	-
	Yes	0	0,0%	-	-
Decemented Interfaces	No	29	100,0%	-	-
	Yes	0	0,0%	-	-
Multi-Unit Unscrewing	No	26	89,7%	74,9%	5,7%
	Yes	3	10,3%	3,0%	5,7%
Prosthetic Screw Unscrewing	No	28	96,6%	85,0%	3,4%
	Yes	1	3,4%	0,4%	3,4%
Plaque	No	23	79,3%	62,2%	7,5%
	Yes	6	20,7%	9,1%	7,5%

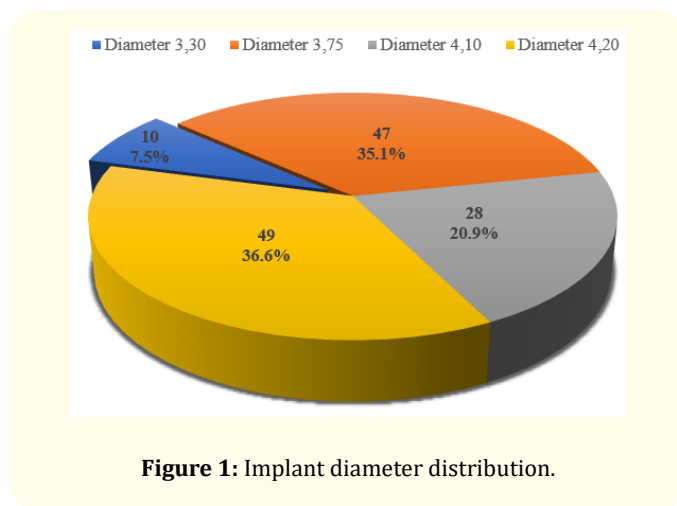
**Table 3:** Summary statistics for rehabilitation characteristics.

		Maxilla	Mandible	Total
Follow-up (months)	Average	15,1	18,4	16,7
	Median	14,0	19,0	15,0
	Standard Deviation	12,4	14,1	13,1
	Minimum	2,0	2,0	2,0
	Maximum	38,0	38,0	38,0
	Percentile 25	4,0	4,0	4,0
	Percentile 75	24,0	27,0	25,0
DVO (mm)	Average	65,1	64,1	64,6
	Median	65,0	63,0	63,0
	Standard Deviation	3,7	5,1	4,4
	Minimum	61,0	56,0	56,0
	Maximum	73,0	73,0	73,0
	Percentile 25	62,0	62,0	62,0
	Percentile 75	67,0	67,0	67,0
AP Distance (mm)	Average	19,6	14,2	17,0
	Median	18,8	13,3	15,9
	Standard Deviation	4,5	3,6	4,9
	Minimum	11,9	10,4	10,4
	Maximum	28,5	23,0	28,5
	Percentile 25	15,9	11,2	13,2
	Percentile 75	23,4	15,9	19,7
Cantilever (mm)	Average	7,8	9,5	8,6
	Median	7,2	9,8	9,2
	Standard Deviation	3,3	3,7	3,5
	Minimum	3,3	,0	,0
	Maximum	14,8	14,7	14,8
	Percentile 25	5,4	8,0	6,2
	Percentile 75	9,6	12,0	11,3
Prosthesis weight (g)	Average	43,0	33,1	38,2
	Median	43,0	34,2	38,7
	Standard Deviation	5,9	4,8	7,3
	Minimum	32,2	24,2	24,2
	Maximum	50,7	38,9	50,7
	Percentile 25	39,3	29,3	33,8
	Percentile 75	46,7	37,5	43,0
Last follow-up (months)	Average	12,9	9,4	11,2
	Median	6,0	4,5	5,0
	Standard Deviation	12,7	10,0	11,4
	Minimum	2,0	2,0	2,0
	Maximum	38,0	30,0	38,0
	Percentile 25	3,0	2,0	3,0
	Percentile 75	23,0	12,0	18,0

**Table 4:** Summary statistics for quantitative measures of rehabilitation.

Smoker * Plaque Crosstabulation					
		No	Tartarus		Total
		Yes			
Smoker	No	Count	19	5	24
		% within Smoker	79,2%	20,8%	100,0%
		% within Plaque	82,6%	83,3%	82,8%
		% of Total	65,5%	17,2%	82,8%
	Yes	Count	4	1	5
		% within Smoker	80,0%	20,0%	100,0%
		% within Plaque	17,4%	16,7%	17,2%
Total		Count	23	6	29
% within Smoker			79,3%	20,7%	100,0%
% within Plaque			100,0%	100,0%	100,0%
% of Total			79,3%	20,7%	100,0%

**Table 5:** Association test results for the presence of plaque and smoking habits.



**Figure 1:** Implant diameter distribution.

**Discussion**

In this study, 21 patients were evaluated, of which their distribution by gender was 8 male patients, corresponding to 38.1% of the sample and 13 female patients, corresponding to 61.9% of the sample.

The facial type did not have a statistically significant influence on the performance of monolithic zirconia, finding 4.8% of Dolicho-

		Diameter							
		3,30		3,75		4,10		4,20	
		N	%	N	%	N	%	N	%
Zone	Mandible	8	13,3%	19	31,7%	12	20,0%	21	35,0%
	Maxilla	2	2,7%	28	37,8%	16	21,6%	28	37,8%

Table 6: Implant diameter distribution according to location.

Diameter									
		3,30		3,75		4,10		4,20	
Tooth	N	%	N	%	N	%	N	%	
T12	1	8,3%	6	50,0%	1	8,3%	4	33,3%	
T14	0	0,0%	4	40,0%	3	30,0%	3	30,0%	
T16	0	0,0%	4	26,7%	4	26,7%	7	46,7%	
T22	1	8,3%	6	50,0%	1	8,3%	4	33,3%	
T24	0	0,0%	5	45,5%	3	27,3%	3	27,3%	
T26	0	0,0%	3	21,4%	4	28,6%	7	50,0%	
T32	1	8,3%	7	58,3%	3	25,0%	1	8,3%	
T34	1	9,1%	2	18,2%	3	27,3%	5	45,5%	
T36	2	28,6%	1	14,3%	0	0,0%	4	57,1%	
T42	1	8,3%	7	58,3%	3	25,0%	1	8,3%	
T44	1	9,1%	2	18,2%	3	27,3%	5	45,5%	
T46	2	28,6%	0	0,0%	0	0,0%	5	71,4%	

Table 7: Diameter distribution according to tooth.

facials, 52.4% of Brachyfacials and 42.9% of Mesofacials, this factor was not evaluated in any of the studies on monolithic zirconia revised.

The centric and eccentric bruxism was not found in any of the patients at the end of the treatment, perhaps because they had recovered stability of the jaws and temporomandibular joint.

In this study, 15 maxillas (51.7%) and 14 mandibles (48.3%) were found in a total of 29 arches, 10 implants were also identified 3.30 NC (7.5%), 47 implants 3.75 RC (35.1%), 28 implants 4.10 RC (20.9%) and 49 implants 4.20 RC (36.6%), with a balanced sample in order to be able to evaluate a sufficient number of cases in both jaws.

Fixed rehabilitations performed with C1 Mis® implants in 69% of patients and BLT Straumann® in 31% of patients had a 100% survival rate.

The success rate of fixed implant-supported zirconia rehabilitations was identical with the All-on-4 technique in 65.5% of patients and All-on-6 in 31% of patients and 3.4% of patients was applied to the 4 Axial implant technique with identical results to Krekmanov, *et al.* and several other authors who addressed the subject of inclined implants [19-30].

The immediate provisional load applied to 41.4% of treated patients did not interfere with the success of fixed implant-supported rehabilitations in monolithic zirconia. Most articles reviewed do not specify the type of temporary prosthesis used during the osteo-integration period.

Regarding antagonist arches, 20.7% have natural teeth, 55.2% have full arch monolithic screw retained zirconia restorations and 20.7% have full arch screw retained metalloacrylic restorations.

The OVD of the patients in this study ranged between 56.0 mm and 73.0 mm and with an average of 64.6 mm measured with a Willis® caliper; this parameter was not mentioned in any of the articles revised.

The follow-up time in the present study ranged from 6 to 38 months with a mean of 15.1 months in the maxilla and 18.4 months in the mandible. Despite the fact that follow-up time is still scarce, the performance of rehabilitations in monolithic zirconia presents very promising results.

The average AP distance was 19.6 mm in the maxilla and 14.2 mm in the mandible, which allowed achieving, even in cases with little posterior bone availability, using the All-on-4 technique, an average cantilever of 7.8 mm in the maxilla and 9.5 mm in the mandible, which it fulfills. with the proposal by English C [31] regarding the distal cantilever of fixed prostheses that never exceeded 1.5x

the AP distance and ensure that the cantilever did not exceed 12 mm in the mandible and 8 mm in the maxilla due to the lower bone density presented in the upper jaw. Statistical tests performed comparing the AP and the cantilever distance verified that this difference is greater in maxillary rehabilitations.

Regarding the fractures occurred only in mandibular rehabilitation and statistically this data corresponds to a percentage of 3.4%. This value is higher than that found by Bidra A who obtained a fracture rate of 1.4% [34] and lower than that of Limmer B who reported 2 cases of fracture of the structure and 2 cases of fracture in the area of the pillars in 17 patients without statistical analysis [38].

The chippings in our study were not found since monolithic zirconia was used in the entire dental portion of the rehabilitation, Bidra A in their study reports 14.7% of chipping [34], Papaspyridakos P in a case report of 3 cases in a 24-month follow-up reports repetition of one of the cases of chipping in the stratified zone [35], Larsson C, in a study with 20 patients reports 40% of chipping in the stratified zone [42], Limmer B in a study of 17 patients reports that 6 had chipping [38], Caramês J, in a study of 14 patients reports only one case of chipping [41]. All the studies mentioned mention high incidences of chipping, which reveals the great advantage of performing 100% monolithic rehabilitations in the dental area, as in our study, as stated by Pinhas A [36].

The wear on the antagonist arch in our study was 6.9%, which is a relatively low result similar to that found by Cardelli P [37] and Sadid-Zadeh R [40].

Regarding the average weight in grams measured with a Mestra® precision digital scale in our study, upper jaw rehabilitations weighed 43g on average ranging between 32.2g and 50.7g and mandibular rehabilitations weighed 33.1g on average, ranging between 24.2g and 38.9g. It is not possible to establish any numerical correlation with other articles as the weight of zirconia restorations was not measured in any of them, only Pozzi A states that zirconia restorations are lighter than metal-ceramic restorations [39].

The decementation of titanium interfaces to zirconia structures did not occur in any of the patients, which reveals that the labora-

tory protocol for cementing them was efficient in all patients. This parameter is rarely mentioned in the reviewed articles, only Limmer B mentions a case of decementation in her study in 17 patients [38]. It was not possible to establish a relationship between this parameter and the facial type since there was no case of decementation in our sample in any of the 3 facial types.

In this study, the unscrewing of multi-units occurred in 10.3% and the unscrewing of the prosthetic screw occurred in 3.4%. quantify statistically, but noting that unscrewing had no influence on the high success rate of fixed implant-supported metalloacrylic rehabilitations [22].

None of the patients used an occlusal splint in order to correctly assess the performance of monolithic zirconia without introducing the splint as an additional factor that could alter the results.

All maintenance was performed every six months from the day of placement of the fixed prosthesis in monolithic zirconia.

The percentage of smoking patients in this study was 23.8% and it was not possible to establish a correlation between the smoking habit and the presence of plaque in fixed rehabilitations in zirconia. It is interesting to note that none of the articles mentioned in the literature on fixed implant-supported rehabilitations in monolithic zirconia addresses the issue of the presence of plaque in the follow-up of zirconia and whether the smoking habit contributes to greater formation of plaque, results identical to those of Linkevicius T [32,33].

## Conclusion

This retrospective study shows that total rehabilitations in monolithic zirconia milled in Cad-Cam are a valid treatment modality for total fixed rehabilitation over implants showing a high clinical success rate and excellent results in terms of patient satisfaction from an aesthetic and phonetic point of view.

Monolithic zirconia milled in Cad-Cam does not require many occlusal adjustments and at follow-ups from 4 to 38 months, it showed full maintenance of the occlusal schemes left on the placement day.

The rate of complications was relatively low and, as suggested by several authors, the fact that the tooth portion was completely executed in monolithic zirconia allowed to reduce chippings to zero; and due to the 4 layers presented in the used zirconia, only with the application of stains allowed to obtain a very favorable aesthetic result in all cases.

All jaws were rehabilitated with screw-retained fixed prostheses, which simplifies peri-implant maintenance and allows treatment reversibility. The use of monolithic zirconia did not cause any damage to the implants and temporomandibular joint or patient dissatisfaction in cases of monolithic bimaxillary zirconia.

Soft tissue biocompatibility was another positive aspect to be highlighted in this study, even patients with longer follow-up time or smokers did not present plaque accumulations; that are typical in metalloacrylic fixed rehabilitations.

We can safely say that the monolithic zirconia Noritake Katana® multilayer ML milled in Wieland® Cad-Cam to perform the fixed rehabilitation of total edentulous arches is a valid treatment option. Featuring a success rate of 96,6%. The result in this study show a high success rate in terms of function, aesthetics and phonetics achieving high patient satisfaction.

### Conflict of Interest

The authors declares that there is no conflict of interest regarding the publication of this article.

### Bibliography

- World Population Prospects, United Nations Department of Public information - The 2015 Revision.
- Peterson PE, Yamamoto T. Improving the oral health of older people: the approach of the WHO Global Oral Health Programme. *Community Dent Oral Epidemiol.* 2005;33(2):81-92.
- Douglass CW, Shih A, Ostry L. Will there be a need for complete dentures in the United States in 2020? *J Prosthet Dent.* 2002;87(1):5-8.
- Rojas-Vizcaya F. Full zirconia fixed detachable implant-retained restorations manufactured from monolithic zirconia: clinical report after two years in service. *J Prosthodont.* 2011;20(7):570-576.
- Larsson C, Von Steyern PV. Implant-supported full-arch zirconia-based mandibular fixed dental prostheses. Eight-year results from a clinical pilot study. *Acta Odontologica Scandinavica.* 2012;71(5):1118-1122.
- Guess PC, Att W, Strub JR. Zirconia in fixed implant prosthodontics. *Clin Implant Dent Relat Res.* 2012;14(5):633-645.
- Kanat B, Cömlekoglu EM, Dündar-Çömlekoglu M, Hakan Sen B, Özcan M, Ali Güngör M. Effect of various veneering techniques on mechanical strength of computer-controlled zirconia framework designs. *J Prosthodont.* 2014;23(6):445-455.
- Sadid-Zadeh R, Liu PR, Aponte-Wesson R, O'Neal SJ. Maxillary cement retained implant supported monolithic zirconia prosthesis in a full mouth rehabilitation: a clinical report. *J Adv Prosthodont.* 2013;5(2):209-217.
- Zaghoul HH, Younis JF. Marginal fit of implant-supported all-ceramic zirconia frameworks. *J Oral Implantol.* 2013;39(4):417-424.
- Limmer B, Sanders AE, Reside G, Cooper LF. Complications and patient-centered outcomes with an implant-supported monolithic zirconia fixed dental prosthesis: 1-year results. *J Prosthodontics.* 2014;23(4):267-275.
- Oliva J, Oliva X, Oliva JD. All-on-three delayed implant loading concept for the completely edentulous maxilla and mandible: a retrospective 5-year follow-up study. *Int J Oral Maxillofac Implants.* 2012;27(6):1584-1592.
- Papaspyridakos P, Lal K. Immediate loading of the maxilla with prefabricated interim prosthesis using interactive planning software, and CAD/CAM rehabilitation with definitive zirconia prosthesis: 2-year clinical follow-up. *J Esthet Restor Dent.* 2010;22(4):223-234.



13. Pozzi A, Holst S, Fabbri G, Tallarico M. Clinical reliability of CAD/CAM cross-arch zirconia bridges on immediately loaded implants placed with computer-assisted/template-guided surgery: a retrospective study with a follow-up between 3 and 5 years. *Clin Implant Dent Relat Res*. 2015;17(1):86-96.
14. Larsson C, Vult von Steyern P, Nilner K. A prospective study of implant-supported full-arch yttria-stabilized tetragonal zirconia polycrystal mandibular fixed dental prostheses: three-year results. *Int J Prosthodont*. 2010;23(4):364-369.
15. Papaspyridakos P, Lal K. Complete arch implant rehabilitation using subtractive rapid prototyping and porcelain fused to zirconia prosthesis: a clinical report. *J Prosthet Dent*. 2008;100(3):165-172.
16. Sherif S, Susarla HK, Kapos T, Munoz D, Chang BM, Wright RF. A systematic review of screw-versus cement-retained implant-supported fixed restorations. *J Prosthodont*. 2014;23(1):1-9.
17. Nissan J, Narobai D, Gross O, Ghelfan O, Chaushu G. Long-term outcome of cemented versus screw-retained implant-supported partial restorations. *Int J Oral Maxillofac Implants*. 2011;26(5):1102-1107.
18. Sailer I, Mühlemann S, Zwahlen M, Hämmerle CH, Schneider D. Cemented and screw-retained implant reconstructions: a systematic review of the survival and complication rates. *Clin Oral Implants Res*. 2012;23(6):163-201.
19. Krekmanov L, Kahn M, Rangert B, Lindstrom H. Tilting of Posterior Mandibular and Maxillary Implants for Improved Prosthesis Support. *Int J Oral Maxillofac Implants*. 2000;15(3):405-414.
20. Francetti L, Romeo D, Corbella S, Taschieri S, Del Fabbro M. Bone level changes around axial and tilted implants in full-arch fixed immediate restorations. Interim results of a prospective study. *Clin Implant Dent Relat Res*. 2012;14(5):646-654.
21. Crespi R, Vinci R, Capparé P, Romanos GE, Gherlone E. A Clinical Study of Edentulous patients rehabilitated According to the "all on 4" Immediate Function Protocol. *International J Oral Maxillofac Implants*. 2012;27(2):428-434.
22. Malo P, Nobre MA, Lopes A, Moss SM, Molina GJ. A longitudinal study of the survival of All-on-4 implants in the mandible with up to 10 years of follow-up. *J Am Dent Assoc*. 2011;142(3):310-320.
23. Kallus T, Henry P, Jemt T, Jorneus L. Clinical evaluation of angulated abutments for the Branemark system: a pilot study. *Int J Oral Maxillofac Implants*. 1990;5(2):39-45.
24. Mattsson T, Kondell PA, Gynther GW, Fredholm U, Bolin A. Implant treatment without bone grafting in severely resorbed edentulous maxillae. *J Oral Maxillofac Surg*. 1999;53(3):281-287.
25. Aparício C, Perales P, Rangert B. Tilted implants as an alternative to maxillary sinus grafting: a clinical, radiologic, and periotest study. *Clin Implant Dent Res*. 2001;3(1):39-49.
26. Fortin Y, Sullivan RM, Rangert BR. The Marius Implant Bridge: Surgical and Prosthetic Rehabilitation for the Completely Edentulous Upper Jaw with Moderate to Severe Resorption: A 5-Year Retrospective Clinical Study. *Clin Implant Dent Relat Res*. 2002;4(2):69-77.
27. Aparicio C, Rangert B, Sennerby L. Immediate/Early Loading of Dental Implants: A Report from the Sociedad Espanola de Implantes World Congress Consensus Meeting in Barcelona, Spain 2002. *Clin Implant Dent Relat Res*. 2003;5(1):57-60.
28. Calandriello R, Tomatis M. Simplified Treatment of the Atrophic Posterior Maxilla via Immediate/Early Function and Tilted Implants: A Prospective 1-Year Clinical Study. *Clin Implant Dent Relat Res*. 2005;7(1):S1-S12.
29. Rosen A, Gynther G. Implant Treatment Without Bone Grafting in Edentulous Severely Resorbed Maxillas: A Long-Term Follow-Up Study. *J Oral Maxillofac Surg*. 2007;65(5):1010-1016.
30. Capelli M, Zuffetti F, Del Fabbro M, Testori T. Immediate Rehabilitation of the Completely Edentulous Jaw with Fixed Prostheses Supported by Either Upright or Tilted implants: A Multicenter Clinical Study. *Int J Oral Maxillofac Implants*. 2007;22(4):639-644.

31. English CE. Critical A-P Spread. *Implant Soc.* 1990;1(1):2-3.
32. Linkevicius T, Vaitelis J. The effect of zirconia or titanium as abutment material on soft peri-implant tissues: a systematic review and meta-analysis. *Clin Oral Implants Res.* 2015;26(11):139-147.
33. Linkevicius T. The Novel Design of Zirconium Oxide-Based Screw-Retained Restorations, Maximizing Exposure of Zirconia to Soft Peri-implant Tissues: Clinical Report After 3 Years of Follow-up. *Int J Periodontics Restorative Dent.* 2017;37(1):41-47.
34. Bidra AS, Rungruanganunt P, Gauthier M. Clinical outcomes of full arch fixed implant-supported zirconia prostheses: A systematic review. *Eur J Implantol.* 2017;10(1):35-45.
35. Papaspyridakos P, Kang K, DeFuria C, Amin S, Kudara Y, Weber HP. Digital workflow in full-arch implant rehabilitation with segmented minimally veneered monolithic zirconia fixed dental prostheses: 2-year clinical follow-up. *J Esthet Restor Dent.* 2018;29(3):178-188.
36. Adar P. Limitless Possibilities with Full-Arch Zirconia Monolithic Hybrid Restorations. *Compend Contin Educ Dent.* 2017;38(3):163-168.
37. Cardelli P, Manobianco FP, Serafini N, Murmura G, Beuer F. Full-Arch, Implant-Supported Monolithic Zirconia Rehabilitations: Pilot Clinical Evaluation of Wear Against Natural or Composite Teeth. *J Prosthodont.* 2016;25(8):629-633.
38. Limmer B, Sanders AE, Reside G, Cooper LF. Complications and Patient-Centered Outcomes with an Implant-Supported Monolithic Zirconia Fixed Dental Prosthesis: 1 Year Results. *J Prosthodont.* 2014;23(4):267-275.
39. Pozzi A, Tallarico M, Barlattani A. Monolithic lithium disilicate full-contour crowns bonded on CAD/CAM zirconia complete-arch implant bridges with 3 to 5 years of follow-up. *J Oral Implantol.* 2015;41(4):450-458.
40. Sadid-Zadeh R, Liu PR, Aponte-Wesson R, O'Neal SJ. Maxillary cement retained implant supported monolithic zirconia prosthesis in a full mouth rehabilitation: a clinical report. *J Adv Prosthodont.* 2013;5(2):209-217.
41. Carames J, Suinaga LT, Yu YCP, Perez A, Kang M. Clinical Advantages and Limitations of Monolithic Zirconia Restorations Full Arch Implant Supported Reconstruction: Case Series. *Int J Dent.* 2015;2015:392496.
42. Larsson C, Von Steyern PV. Implant-supported full-arch zirconia-based mandibular fixed dental prostheses. Eight-year results from a clinical pilot study. *Acta Odontol Scand.* 2013;71(5):1118-1122.

**Volume 4 Issue 9 September 2021**

© All rights are reserved by Fernando Duarte., et al.